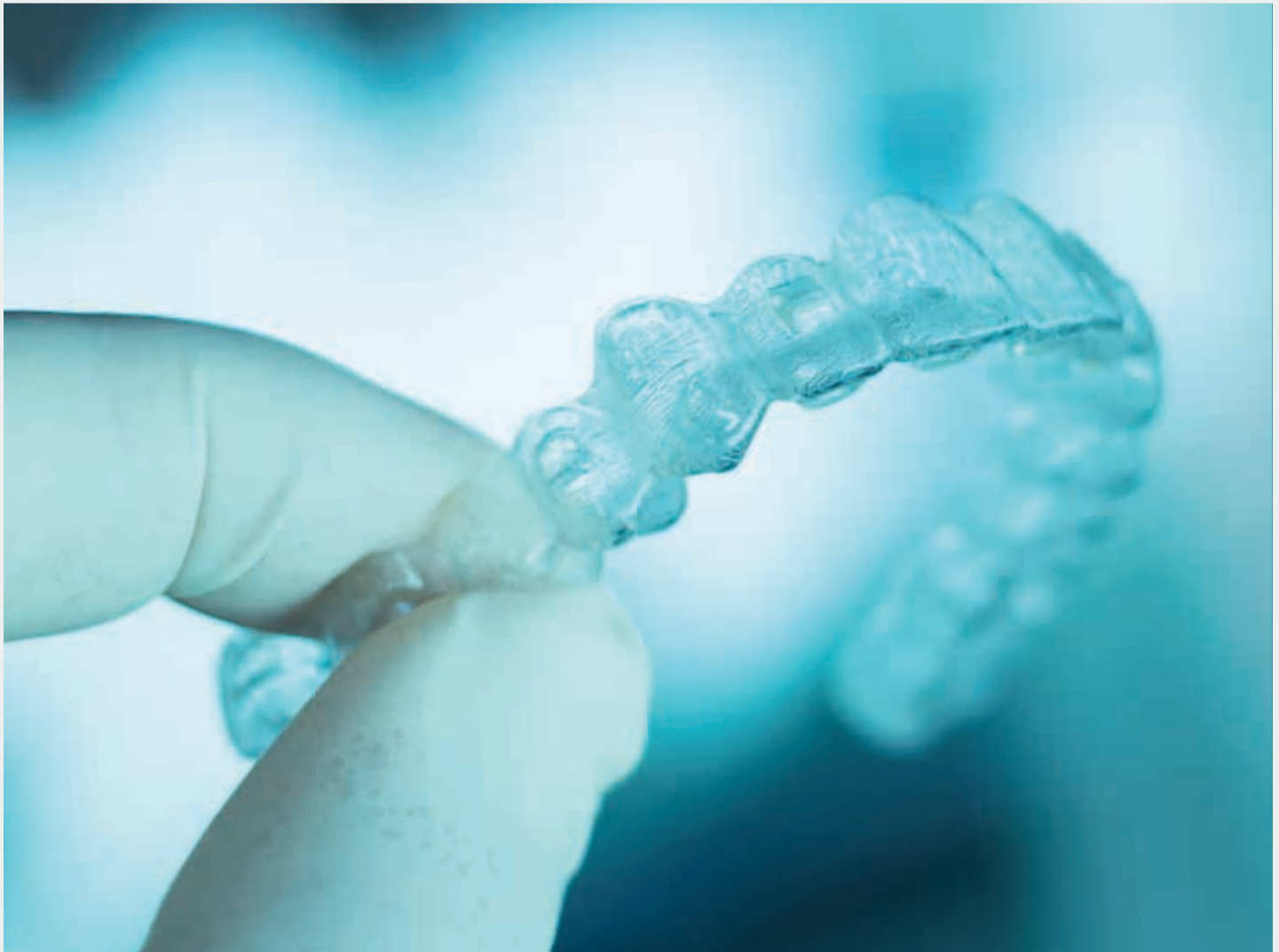



RISKWISE

ISSUE 21 | NOVEMBER 2019

CARIBBEAN AND BERMUDA



The increase in orthodontics and the risks that might arise

The clear aligner market is increasing but it has potential limitations.

The sum of all fears
How can we manage risk and uncertainty?

Erosive tooth wear
One of the most common oral conditions dentists see.

Case studies
Practical advice from real life scenarios.



EXCELLENCE AS STANDARD

Your career deserves the best protection possible. It deserves Dental Protection.

INDEMNITY YOU CAN DEPEND ON

There are no financial limits on the indemnity we can provide.

HANDLING CASES WITH CONFIDENCE

In 2018, members benefited from our unrivalled experience in 6,625 dental cases worldwide.

FIGHTING YOUR CORNER WITH REGULATORY PROCEEDINGS

Where others won't, we can offer protection against investigations into personal conduct matters.

ADVICE WHEN YOU NEED IT

The largest worldwide team of dentolegal experts just a phone call away.

Find out more at dentalprotection.org/excellence

Contents




05 The increase in orthodontics and the risks that might arise

Dentolegal Adviser Dr Simon Parsons looks into the complexity of orthodontics, the potential limitations and the risks that might arise.



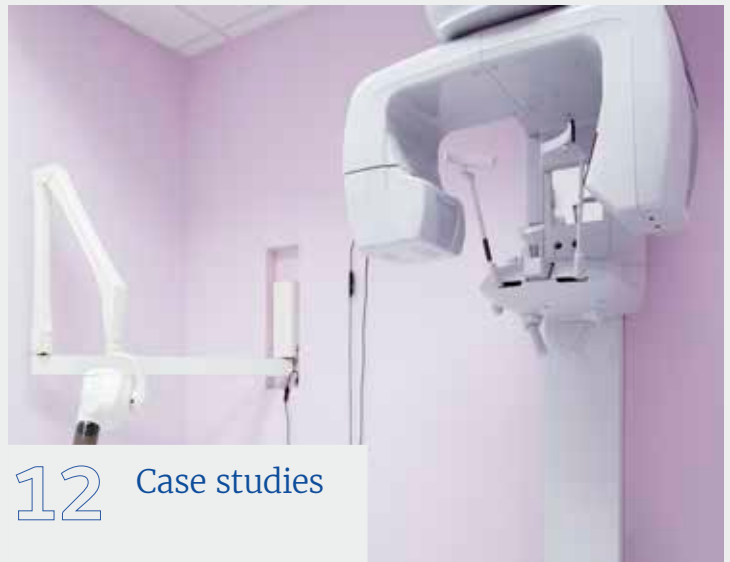08 The sum of all fears

Raj Rattan, Dental Director at Dental Protection, looks at how we can stay confident and competent throughout our careers.



10 Monitoring erosive tooth wear

Professor Bartlett and Dr Dattani examine the importance of documenting tooth wear as part of a standard dental examination.



12 Case studies

From the case files: practical advice and guidance from real life scenarios.

Editor

Anna Francis

Design

Emma Senior

Print

Spellman Walker

Contributors

Simrit Ryatt, Louise Eggleton, Jim Lafferty



Editorial



JOE INGHAM
DENTOLEGAL CONSULTANT

Welcome

Hello and welcome to your latest edition of *Riskwise*. We have put together this publication based on a variety of dentolegal topics which I trust you will find informative and helpful.

Our patients are tending to live longer and are retaining more of their natural dentition when compared to previous generations. Tooth surface loss is starting to feature more in the advice we need to give patients as well as the treatment being provided. Professor Bartlett and Dr Dattani have provided us with a very informative article for this edition, talking through how monitoring erosive tooth wear is likely to become commonplace in day-to-day practice. On page 17, dentolegal consultant, Jim Lafferty, talks to us more about cone beam computerised tomography – not something that all practitioners will be familiar with, but a tool that is becoming increasingly popular with our colleagues in specialist practice.

Other articles have a theme running through them that can loosely be described as ‘human factors.’ These range from maintaining a professional and ethical stance at all times to ensuring that effective communication with patients results in a robust consent process. Our Dental Director, Dr Raj Rattan, has written a very thought-provoking article on the management of fear and uncertainty and how this relates to practising dentistry.

We realise only too well how stressful a challenge to one’s professional reputation can be. This can take the form of a simple patient complaint, a claim for compensation or a full-blown investigation by the regulator.

Last year, Dental Protection carried out a survey of more than 1,000 dentists. This revealed that 90% of those questioned were increasingly fearful of being sued by their patients.

My own anecdotal research reveals that exactly the same sentiment is present amongst hygienists. Three-quarters of those questioned feel that the fear of being sued impacts upon the way they practise. This can lead to clinicians practising ‘defensive dentistry’ – when treatment is provided not necessarily with the patient’s best interests in mind but rather with a view to reducing the risk of being sued. Clearly it is not possible to completely eliminate risk, especially when an intrusive profession such as dentistry is involved. You can be reassured that Dental Protection has the knowledge and expertise to guide and support its members whenever the need arises.

It may be worth reminding you that all members have access to Dental Protection’s online educational platform – Prism. There is a wealth of information there which can assist you in understanding and mitigating the risks associated with practising dentistry.

As ever, we are always interested to have your feedback and suggestions as to what you would like to see covered in future publications.

With very best wishes

Joe Ingham BDS LLM FFFLM
Dentolegal Consultant and Editor in Chief *Riskwise*
Caribbean and Bermuda

joe.ingham@dentalprotection.org



The increase in orthodontics and the risks that might arise

With the clear aligner market increasing around the world, dentolegal adviser Dr Simon Parsons looks into the complexity of orthodontics, the potential limitations and the risks that might arise.

The worldwide USD \$3bn per annum clear aligner market is forecast to continue growing by around 21% over the five year period of 2018-2023.¹

General dentists with limited prior orthodontic training may be drawn to the promise of aligner systems that seem almost to 'do it all' and are increasingly offering this treatment to their patients. This opportunity to augment practice revenue, and grow one's clinical skill set, brings in its wake the increased likelihood of complaints and claims

when the treatment outcome is compromised or patient expectations have not been met.

The provision of orthodontic treatment by general dental practitioners can be risky, even when it involves modest tooth movement. The importance of case selection cannot be overstated and unmet expectations can trigger litigation. When cases arise, it is not uncommon for general practitioners to be questioned about the extent and adequacy of their training to undertake orthodontic treatment.

A recent study carried out in the United States investigated the different perceptions of case complexity between orthodontists, GDPs, orthodontic trainees and dental students. The study concluded that orthodontists and orthodontic trainees "...had better judgments for evaluating orthodontic case complexity. The high correlation between orthodontic professionals' perceptions and DI scores suggested that additional orthodontic education and training have an influence on the ability to recognize case complexity".²

LOOKING AT THE LIMITATIONS

Although clear aligner systems have some clinical advantages and are based on sophisticated technology, they have limitations in the amount and type of tooth movement that can be achieved.³

Furthermore, there is some evidence of unexpected risks with aligner therapy, such as breathing difficulty, swelling of the lips, throat and tongue and even anaphylaxis.⁴ These risks must be appropriately managed.

As a third party usually provides the initial treatment planning for aligner cases, it may be tempting to delegate the decisions in a patient's orthodontic management to an unseen party who is relying on supplied photographs, scans and models. Inexperienced dentists may not recognise that targets for tooth movement, derotation and intrusion or extrusion are ambitious. The achievement of a successful aesthetic and functional result may well depend on completing all these actions, and the treating dentist will be responsible for the treatment outcome should it fail to meet patient expectations.

The high costs of orthodontic care, and the patients' capacity to evaluate the outcome, will go a long way towards the patient's perception of success. There will undoubtedly be high expectations on the part of the patient and, if these are not met, referral for specialist treatment may be indicated which will incur additional costs. Uncertainty can exist in the minds of general dentists and patients as to who is responsible for any costs associated with corrective treatment, or when a patient transfers to another practitioner prior to completion. So how might dentolegal risk

be reduced when general dentists consider offering clear aligner treatment?

PRE-TREATMENT

Making an accurate diagnosis is the first step in understanding patient suitability for treatment by a general dentist. Poor case selection is frequently the root cause of dissatisfaction down the line. Pre-treatment assessment might include detection of unfavourable facial profiles, marked asymmetries, a deep overjet and overbite or substantial midline discrepancies which may prove difficult to manage with clear aligners alone. It can be tempting to offer patients an improvement in tooth position through aligner therapy while unknowingly ignoring underlying factors that may make success almost impossible to achieve without specialist care.

Appealing as it may be to take on a case, it is always wise to discuss alternatives to clear aligner therapy with a patient, including such options as no treatment and specialist referral. Simply because a patient has attended for a consultation or sought information about clear aligners - sometimes as a result of internal marketing - does not mean that this is the only option that should be considered. The dentist must consider all other viable alternatives in consultation with the patient as part of the consent process.

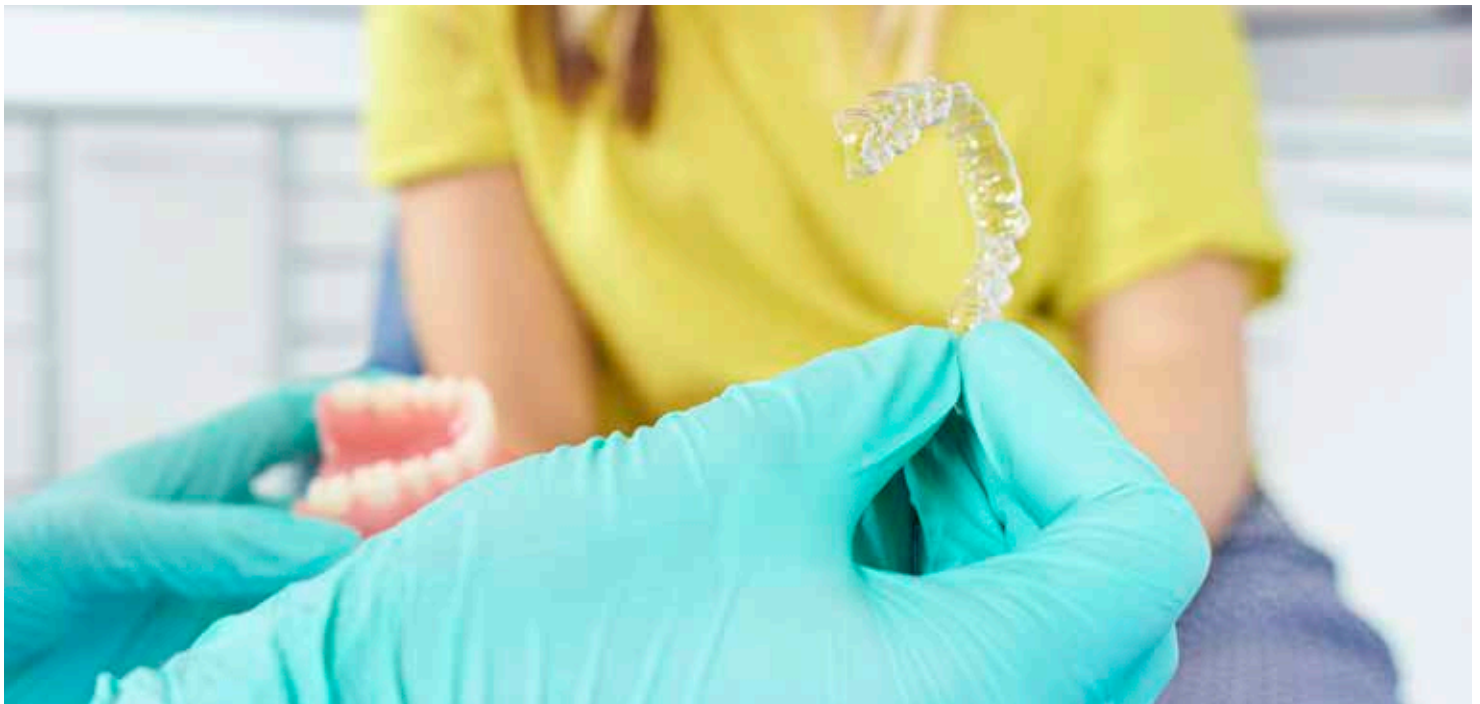Understanding the patient's expectations from the outset is essential to avoid future disappointment. Some patients who seek aligner therapy may present with minor orthodontic needs, but may expect absolute perfection in tooth alignment. Indeed, their expectations may involve other factors which they, themselves, do not fully understand such as the shape of individual

teeth or the colour of some or all of their teeth. Any non-compliance with aligner wear or post-treatment retention may compromise the outcome and achievement of ideal results. The clinical presentation, diagnosis, treatment options, risks, benefits and costs, importance of compliance with advice and tempering of unrealistic patient expectations should all be documented in the clinical records together. These entries will be scrutinised in the event of any investigation or inquiry.

DURING TREATMENT

Problems such as speech concerns, excessive salivation, mouth soreness, aligner breakage and aligner loss may all impact on treatment effectiveness. Patients may dislike attachments placed on teeth, fail to use elastics or other adjuncts to treatment or decline to undergo interproximal tooth reduction. A prospective patient needs to be aware of these issues, before and during treatment, so that there are no surprises and disagreement as treatment progresses.

Despite the best efforts of both the patient and the clinician, sometimes treatment does not progress as well as expected. Dentolegal risk can be reduced through regular patient reviews in surgery rather than an 'arm's length' approach of minimal treatment supervision. Early detection of problems enables prompt correction where possible and helps to avoid escalation of problems and further patient dissatisfaction. Our experience is that it is wise to refer patients to specialist providers promptly whenever the efficacy of aligner treatment seems to be in doubt. This can mitigate the risk of further complications while also optimising the chance of a favourable overall treatment outcome.





POST TREATMENT

While all orthodontic treatment carries risk, some risks may persist upon treatment completion. Patients may be unhappy with the overall treatment outcome and request refinement, retreatment or referral. The general dentist will need to evaluate with the patient how closely the result matches with the pre-treatment projection and the individual patient's long term expectations. Retreatment or referral may carry financial implications for both parties and is best understood before treatment commences (through an explanation) rather than after treatment has finished (via an excuse). Devitalised teeth, relapse, or – particularly with aligners – a failure to achieve adequate occlusal contacts may also occur. Effective retention is essential if relapse is to be avoided.

CASE ASSESSMENT

To manage risk with clear aligner cases, careful case assessment is key. Some aligner systems allow prediction of the final outcome and alteration of the treatment parameters to suit the objectives of the patient and the clinician. These are preferred over a 'one size fits all' approach. Dental Protection recommends any treatment proposal be thoroughly checked prior to finalisation of the treatment plan by the treating clinician to ensure that proposed tooth movements are within a predictably reliable range.

General practitioners have the advantage of coordinating a patient's total dental care, and this provides scope for considering preventive and restorative needs within the overall plan. The general practitioner is well placed to consider any pre-existing limitations to effective tooth movement,

such as implants and bridgework, while also understanding how to manage restoration fracture or loss during aligner treatment. Are you able to deal with complications if they arise? Do you have the knowledge and skill necessary to identify and manage likely complications that might occur during the treatment phase?

As with any treatment that incurs significant financial and time costs, it is always prudent to approach clear aligner therapy alongside other necessary treatment rather than as a standalone treatment. Despite a patient's understandable desire to get on with the cosmetic component first, it is often wise to schedule orthodontic treatment towards the latter stages of any treatment plan. Ensuring all periodontal, endodontic and restorative issues have been addressed first means that the patient is more likely to be a suitable candidate for orthodontic treatment.

REFERENCES

1. Reuters.com. (2019). Clear Aligners Market 2018 Global Trends, Key Vendors Analysis, Industry Growth, Import - Reuters.
2. Heath EM, English JD, Johnson CD, Swearingen EB, Akyalcin S, Perceptions of orthodontic case complexity among orthodontists, general practitioners, orthodontic residents, and dental students, *Am J Orthod Dentofacial Orthop*. 2017 Feb;151(2):335-341. doi: 10.1016/j.ajodo.2016.06.045.
3. Ke Y, Zhu Y, Zhu M, A comparison of treatment effectiveness between clear aligner and fixed appliance therapies. *BMC oral health* 19(1), 24. doi:10.1186/s12903-018-0695-z (2019)
4. Allareddy, Veerasathpurush et al. (2017). Adverse clinical events reported during Invisalign treatment: Analysis of the MAUDE database. *American Journal of Orthodontics and Dentofacial Orthopedics*, Volume 152, Issue 5, 706 - 710

LEARNING POINTS

- Take models/scans, radiographs and photographs as part of a preoperative assessment and evaluate these thoroughly before discussing the feasibility of aligner therapy with your patient.
- Clearly outline the costs of care, including the costs of replacement aligners and retainers. Ensure patients understand when payments are due.
- Carefully explain the process, including composite resin attachments if required, and the importance of compliance. Explain that, occasionally, a specialist referral may be necessary if things do not go to plan. Establish who will be responsible for the costs of such a referral.
- Be on your guard towards patients with unrealistically high expectations or those who seem in a hurry to commence treatment without due consideration to their other treatment needs (such as caries or periodontal issues).
- If in any doubt as to the likelihood of success, consider referral of a patient to a more experienced colleague or specialist.
- If you are not a specialist orthodontist, make sure that the patient is aware of this and offer a referral to a specialist as one of the options for treatment.

The sum of all fears

It is a fact that much of human behaviour is related to maximising rewards and minimising losses. Raj Rattan, Dental Director at Dental Protection, looks at how we can reduce fear and manage risk and uncertainty, so we can stay confident and competent throughout our careers.

The view that success breeds success is explained by neuroscience as the result of a surge in the neurotransmitter dopamine. This reward chemical encourages the brain to carry on doing what it has been doing – it is an example of ‘reward-based learning’. We also learn from failure – so-called ‘avoidance learning’ – where the absence of a stimulus creates a behavioural change. It correlates with the expression of fear.

FEELING THE FEAR

It is a widely expressed view that dentists are now more fearful than ever. We hear it from members, from professional bodies, from those involved in postgraduate education including training programme directors who are in regular contact with foundation dentists.

The fears relate to the consequences of failure, reprimand, and loss of reputation. It impacts self-esteem and may lead to loss of confidence in carrying out clinical procedures, especially when there are pre-existing concerns and self-doubt about clinical competence. These fears are expressed by dentists and the voices have never been louder.

In a bygone age, these voices were heard only by those within earshot. Today, the extended reach of social media means the world can listen and replay. Fears are

amplified and this leads to vicarious fear learning; it appears without any direct contact with the stimulus. An individual learns from another by observing their response to a situation. When one person posts a comment, all readers feel the fear.

Important details are frequently omitted in commentary about dentolegal cases; information and misinformation blended to occupy the same space. Details are a distraction, enforced brevity an asset. This brevity curse has claimed many victims. Incomplete or inaccurate information in bite-sized pieces is easy to exchange and share with the world. It is out there – available to everyone at all times of the day and night.

It leads to availability bias – a type of cognitive bias that distorts the way we see the world. Information that comes to mind quickly and is covered by the media makes us believe that it is very common. Its swift passage through modern communication channels leads inevitably to the bandwagon effect.

Experiments have shown that if a large proportion of people adopt a particular view or stance, then there is a greater probability that others will adopt the same position (regardless of their beliefs). These psychological biases can skew reality, making us feel more vulnerable than we should. In other words, we judge probability

by how easily the information comes to mind rather than the mathematical construct it is.

COMPETENCE AND CONFIDENCE

Fears related to competence may also be influenced by self-perception, but many are well supported. Our experience of dentolegal cases tells us much about the factors that contribute to suboptimal outcomes that form the basis of complaints and litigation.

There are situational and systemic predisposing factors. These include time shortage, target-driven payments systems and other related commercial factors. Studies suggest that unfamiliarity with a task significantly increases the likelihood of error. This is a competency issue and we observe this in a significant number of cases.

Competence is a precursor to doing things right. It is a blend of three ingredients that are required in abundance – procedural knowledge, exposure to varying levels of complexity, and experience. Whilst we often stress the importance of comprehensive and contemporaneous record keeping, the outcome of a case built on competence-related issues is unlikely to be successfully defended on the standard of record keeping alone.

Measurement of competence is the key – both at undergraduate and postgraduate level. There have been many developments in educational theory in the last 100 years,



but Flexner's assertion (1910) that "there is only one sort of licensing test that is significant: a test that ascertains the practical ability of the students confronting a concrete case to collect all the relevant data and to suggest the positive procedures applicable to the conditions disclosed" holds true today. Emotional intelligence, empathy and effective communication may mitigate the consequences of competency-related failures but are not a substitute.

In his thesis, Roudsari (2017) discusses aspects of foundation. He writes that "from the trainers' point of view and based on a recent qualitative study, however, it has been shown that the majority of the newly qualified dentists are far from being competent, in particular due to lack of experience in a number of key dental procedures; for example, endodontics and extraction of teeth with difficulty levels of moderate to hard".

Many foundation dentists that visit us each year during their foundation training express similar concerns. It compounds the fear. We provide bespoke educational programmes to help them overcome these fears and other professional challenges at a critical part of their professional development. We can however do little to increase their clinical competence other than stress its importance as a key risk management principle and suggest solutions to the dilemma.

Literature relating to pre-foundation training competence is scarce because, according to Roudsari, "most of the publications focus on 'confidence' of the graduates and not their 'competence'".

This presents another challenge because an over-reliance on confidence is not without its drawbacks. Confidence is a double-edged sword from a dentolegal perspective. David Dunning and Justin Kruger – Nobel Prize winners for their work – demonstrated the overestimation of performance by individuals of low competency levels. It is observed at low levels of experience, because at this stage an individual has little or no insight into their weaknesses. As a result, these individuals are particularly at risk because they don't know what they don't know. It is equally true at the beginning of a person's career as it is at any stage where a person undertakes postgraduate study to learn new skills.

So, how does a dentist ensure they have the appropriate level of training to undertake clinical procedures? Not all postgraduate courses offer the same training opportunities and there may be different levels of clinical supervision available.

SUMMARY

Patients expect us to be competent. Competence-related issues are as important as all other contributory factors

to effective risk management. We have an ethical obligation to evaluate outcomes and assess personal competence to avoid straying – intentionally and unintentionally – beyond our areas of expertise and training, propelled by misplaced confidence and perverse incentives.

Recognising the influence of availability and bandwagon bias is the first step to deal with risk and uncertainty, and estimate probabilities accurately. It's about being able to gauge the limits of our own knowledge, knowing when we don't know much, and being confident when we do. This contributes to our risk intelligence.

If we are to reduce the sum of all fears, then individual practitioners, educators, regulators and government agencies have an important role to play to understand and address the root causes. The future depends on it.



Monitoring erosive tooth wear

Erosive tooth wear is one of the most common oral conditions dentists see. Professor David Bartlett from King's College London and Dr Soha Dattani of GSK Consumer Healthcare examine the importance of documenting it as part of a standard dental examination.



Despite being one of the most commonly observed oral condition after caries and periodontal disease, erosive tooth wear is currently not routinely screened or monitored as part of the standard dental examination.

With modern lifestyles resulting in a 'snacking' culture, and an ageing population where people are living longer and retaining their teeth into later life, the overall potential tooth wear risk is rapidly increasing. This, coupled with increasing expectations of patients and the public, means that there is an increased potential for litigation in this area.

Managing the consequences of severe erosive tooth wear can be both expensive and time consuming. According to a study by O'Toole et al., costs could be up to USD \$15,680 for private treatment and treatment could take up to 24 months. As with periodontal disease, it is therefore important that examination for erosive tooth wear is part of the routine oral health assessment and clearly documented in the patient's records.

COMMUNICATING RISK FACTORS

We know that communication is key in the dentist/patient relationship. So if a patient frequently snacks on acidic food or drink, at least twice per day between meals, then it's a good idea to discuss with your patient the potential need for treatment at a later date.

A patient's history can reveal a lot about any future treatment they may need. If they suffer from acid reflux or have bad dietary habits, such as swishing or holding drinks in their mouth that may lead to erosive tooth wear, then this should be discussed and noted.

This should be recorded on a 4-point scale (0-3) with 0 indicating no wear; 1 – very early signs such as loss of surface features (perikaymata, softening of the cingular contour); 2 – wear that is visible on a surface but less than 50%; and 3 – over 50%. Like the basic periodontal examination (BPE), all teeth are examined but only the most severe in each sextant are recorded in the notes in the same way as the BPE. A score of three in any sextant or any combined score over

9 should alert the dentist that tooth wear is active and prevention needs to be started. In cases where the teeth become shorter, further advice is needed.

PREVENTION IS BETTER THAN TREATMENT

A patient's attitude may help direct whether prevention or treatment is advised. They may be fully aware of their tooth wear or be completely surprised when told. It's important for dentists to broach the subject delicately, especially with patients where the erosive tooth wear could be down to other conditions such as bulimia.

Talk to your patient and explain the examination findings. If they are worried or suffering from pain, poor function or poor appearance then they may ask for treatment. If possible, the dentist should advise looking at prevention or a minimal intervention treatment to prevent symptoms from reoccurring or getting worse.

Patients with severe erosive tooth wear may need extensive treatment. It's important dentists know when the treatment required is outside their scope of expertise and better referred to a specialist.

MAKING A DECISION

It's key that a patient plays their part in deciding about their teeth and any treatment plan put in place. The dentist must ensure that valid consent has been given by the patient. To secure this, they must have informed the patient what the problem is (including being shown the evidence from the examination) and what treatment options are available (and any risks involved). They also need to talk through the costs that may be associated with a treatment plan.

RECORDING EROSIIVE TOOTH WEAR

Unfortunately, little is known about the natural history and progression risks for erosive tooth wear. For some, progression is slow and gradual, but for others rapid hard tissue destruction occurs that can compromise the longevity of the dentition. Even in late stages, the condition is usually

painless, and the only clinical feature is shortened teeth. It should be noted that as erosive tooth wear is not triggered by high levels of plaque, the condition usually affects the 'committed' patient. In summary, given there are no clinical guides to identify 'at risk' patients, assessment and documentation of erosive tooth wear should occur at every clinical examination.

The Basic Erosive Wear Examination (BEWE) is a well-recognised clinical tool specifically designed for general practice. It has been increasingly adopted internationally and used in 96 peer-reviewed publications in more than 34 countries to date. It follows the same sextant approach as the Basic Periodontal Exam (BPE) and can be conducted at the same time, therefore requiring little additional clinical time. It is not designed to be reproducible but is a straightforward way to record that tooth wear has been examined in the clinical notes.

Keeping accurate, detailed, up-to-date notes including the BEWE results, the decision-making process, the joint decision making process and any actions taken or treatments carried out, is vital in managing risk. If the patient and dentist together decide to just monitor erosive tooth wear then it's key to include this in the patient's notes, to protect against a claim that could be made down the line.

CONCLUSION AND FURTHER RESOURCES

Erosive tooth wear is not routinely assessed and documented as part of the clinical dental examination. The BEWE provides clinicians with a simple screening tool to efficiently detect and document erosive tooth wear in clinical practice. Its use is advocated to protect the oral healthcare provider and the patient, as the prevalence and awareness of this condition increases. Resources and online training for the BEWE can be found at errosivetoothwear.com and gskhealthpartner.com

Case study

Doing the right thing



enytbz/iStock / Getty Images Plus via Getty Images

The G family had attended Dr P's practice over many years. The four children of Mr and Mrs G had been regularly brought in to see their dentist and they continued to attend the practice as adults. The whole family enjoyed a good relationship with Dr P.

Dr P provided treatment for Mr G that included a root canal treatment for his non-vital 9, which Mr G had finally agreed to have done after having put it off for some time. On completion of the RCT, Dr P recommended restoration of the tooth with a post-retained crown and suggested that the heavily restored and discoloured 8 be crowned at the same time. Despite some reservations about the cost, Mr G agreed to this.

Eight months later, Dr P received a letter from an insurance company. It contained various forms related to Mr G that mentioned "his accident". On closer reading, Dr P noted that he was being asked to confirm the treatment that he had provided for Mr G, including the nature, extent and reason for it. The treatment details were pre-printed within the document, with a signed permission form confirming Mr G's consent for Dr P to disclose treatment details.

Dr P was puzzled, as the information did not coincide with his own records. One glaring inaccuracy was the description of two crowns and two root treatments being carried out as a result of trauma. As the information was so inaccurate, Dr P telephoned the insurance company and it was confirmed to him that the information on the form had been provided by Mr G. Dr P did not say anything to contradict this at that point, but was quite concerned as to what he should do and sought advice from Dental Protection.

The content of the letter from the insurance company seemed to indicate that Mr G had submitted an insurance claim against a

company seeking redress for some accident. Dr P did not wish to say anything that was untrue in relation to the claim put forward by his patient but, at the same time, he was very uncomfortable about the potential implications for Mr G and his relationship in correcting the inaccuracy.

Following advice from Dental Protection, Dr P met Mr G at the practice to help clarify the situation. Mr G explained that he had fallen over in the premises of a major store. Although he had not broken anything, he did have some bruising and had submitted a claim to cover the costs of treatment he had required, including painkillers and physiotherapy. He had thought of including his dental care as a way of defraying the costs of his recent treatment and believed that as Dr P was essentially a family friend, he would be able to back him up. Dr P thanked Mr G for helping him to understand the situation more clearly and, after the meeting, immediately sought further advice from Dental Protection.

Although it would be much more convenient for Dr P simply to accommodate his patient, it was clear that would be deliberately misleading and would make him a knowing party to a fraudulent claim. Aside from this action opening the possibility of criminal charges, there is an ethical obligation on registrants to be honest and respect the law.

Following advice from Dental Protection, Dr P wrote to Mr G to explain that he was sorry but, due to being bound by an ethical code of professional conduct, he was not in a position to support his claim by confirming misleading information. To protect the best interests of his patient, Dr P also suggested that Mr G let the matter of his "dental injuries" drop.

Dr P heard nothing further from Mr G about this. The family, however, continued to attend the practice.

LEARNING POINTS

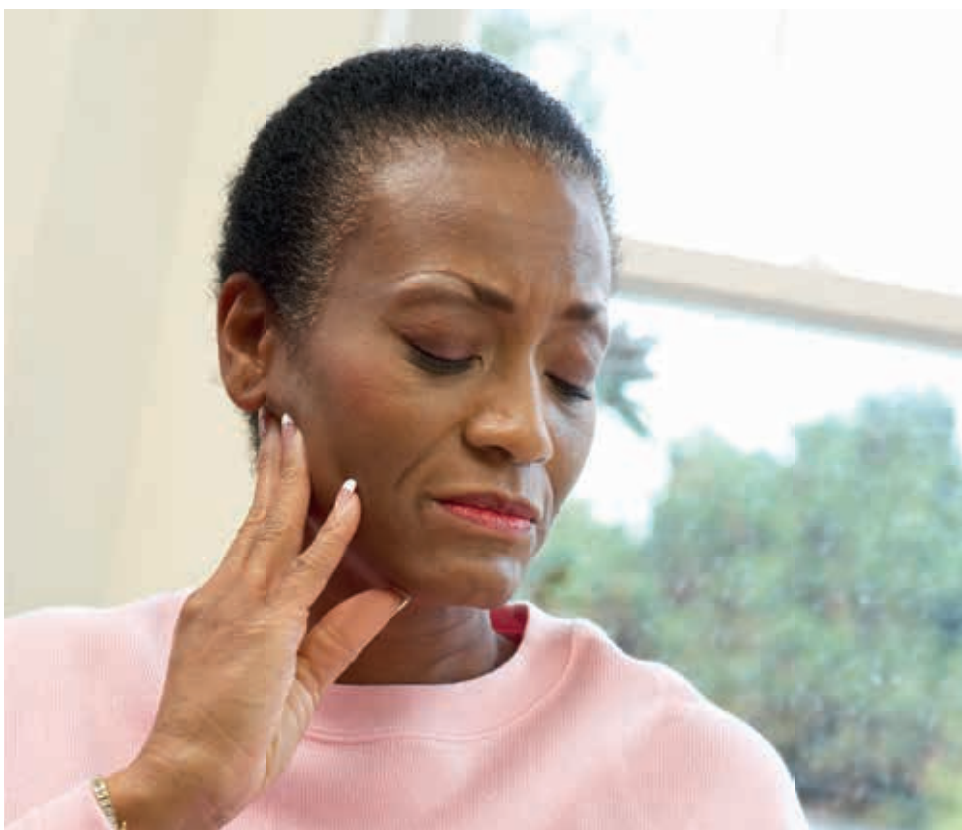- Dentists can sometimes face situations where it might be tempting to go along with an action to accommodate a particular patient. It is important to remember however that in addition to obeying the law, all registrants are bound by an ethical code and have a duty to uphold the reputation of the profession.

Did you know..?

Membership means **you can always ask for help** from our experienced team of case managers and dentolegal consultants.

Case study

A lucky escape



BananaStock / Getty Images Plus via Getty Images

Mrs H, who is 69 years old, attended a new dentist as she was struggling with her lower denture that replaced her missing 20, 19 and 18. She had no other missing teeth apart from third molars, and the space at the lower left was very noticeable to her as she had a broad smile that showed her missing teeth on the lower left side.

Dr L established that Mrs H had lost her 18 due to extensive caries when she was in her late teens. The 18 had been extracted and then replaced with a single cantilever bridge with 19 as the abutment. From the information gathered, it sounded like the 19 had lost vitality and a number of endodontic treatments were attempted but unsuccessful. The 19 was eventually extracted when Mrs H was in her early 20s. She requested that Dr L restore the area with implants.

Mrs H had also brought a panoramic x-ray from a few years ago and Dr L noted the reduced bone height, but he considered there was enough to allow for a safety margin beneath the planned implants. Dr L suggested placing two implants at 20 and 19, with a view to providing an implant retained bridge with 18 as the pontic. Dr L had time to do the treatment the same day and, during the surgery, Mrs H felt intense pain as one of the implants was inserted, even though sufficient local anaesthetic had been administered. The following day, a very agitated Mrs H telephoned the surgery and reported numbness on the lower left side of the lip. As a parting comment she remarked that should her symptoms not improve, she would contact the police.

Dr L immediately contacted Dental Protection to request assistance and it was suggested that he immediately arrange a referral to a maxillofacial specialist. Mrs H was seen promptly and a cone-beam computed tomograph (CBCT) scan was taken, which confirmed the implant fixture at 19 had penetrated the inferior dental canal and had probably mechanically traumatised the left inferior dental nerve (IDN). Sensory nerve testing carried out on the lips indicated that Mrs H could not discern directional

stroking or cold stimulus. The specialist removed the implant fixture at 19 without delay, prescribing steroids and NSAIDs, and he was hopeful a prompt intervention might reduce the risk of permanent nerve damage.

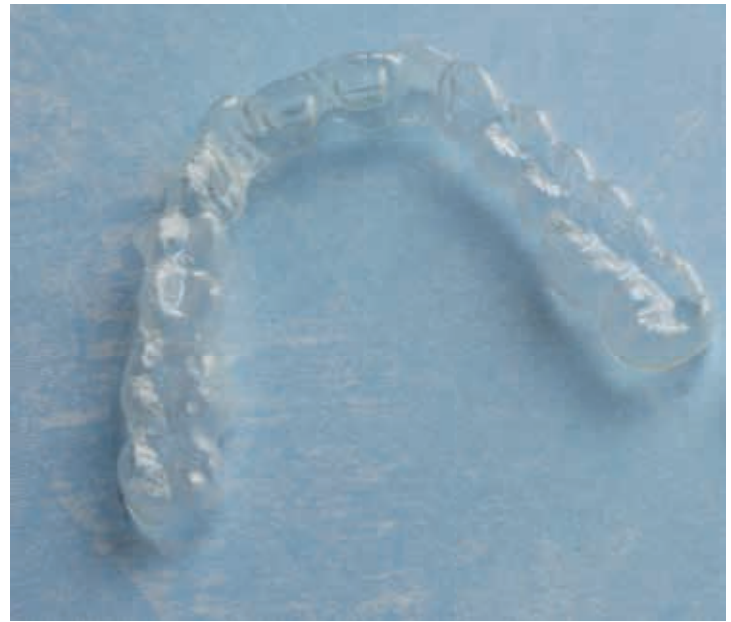After the implant fixture was removed, Mrs H noted an improvement in her symptoms at three months and was kept under review.

LEARNING POINTS

- When Dr L's case was reviewed by his dentolegal consultant it became apparent the assessment and planning fell short of accepted practice. He had not confirmed the date of the panoramic; it was subsequently confirmed he was working from a six-year-old panoramic. On reflection, he now realised that an up-to-date preoperative panoramic should have been taken and a CBCT scan would have been beneficial to further reduce the risk of IDN injury.
- The dentolegal consultant also identified that the treatment records did not show any evidence of a discussion of the risks associated with the treatment. When asked, Dr L could not recall with any certainty whether he had discussed the risks and the potential consequences should that risk materialise.
- Dr L also reflected that it would have been good practice to contact Mrs H following treatment by way of review, so that if any issues arose, steps could be taken to address her concerns or symptoms.
- With hindsight, Dr L recognised that insufficient time had been taken to complete an adequate preoperative assessment and to give Mrs H a cooling off period during which she could think about the treatment and the associated risks.
- She also appreciated the swift recommendation to refer to a specialist, once the nerve injury had been identified, which probably contributed towards the resolution of the IDN damage and perhaps averted any long-lasting damage to his professional reputation.

Case study

Aligning your ethics



RondaKimbrow/E+ via Getty Images

Mr H attended a routine examination appointment and expressed dissatisfaction about the position of his upper anterior incisors and the prominent position of his upper canines. The dentist advised the patient they could provide treatment through a clear aligner system and offered an immediate orthodontic assessment. Mr H agreed and they went on to discuss potential orthodontic treatment within that same appointment.

Mr H informed the dentist that he had received previous orthodontic treatment five years ago, but had never been completely satisfied with the final aesthetic result. The dentist observed Mr H's upper incisors were mildly retroclined, which exaggerated the buccal position of the upper left and right canines.

The dentist informed Mr H that he was a suitable case for treatment with clear aligners and provided an estimate of costs. Mr H was very pleased with the proposal and immediately agreed to go ahead with the proposed plan, with an expectation that the treatment would take between 6-12 months to complete.

Treatment commenced and Mr H and the dentist were happy with the progress made during the first six months. However, as the dentist moved into the final set of aligners, Mr H began to express dissatisfaction with the final position of the canines which, in his opinion, were still too prominent. The dentist informed Mr H that the position of his teeth was now anatomically correct and felt no further treatment was needed. Mr H remained dissatisfied and insisted that further treatment be carried out.

Against the dentist's better judgement, he agreed to provide further treatment with the intention of moving the upper anterior incisors to a pronounced buccal position to help disguise the prominent canines. This

refinement phase continued for a further five months, at which point Mr H complained of discomfort and pain from the upper incisors, and he was now concerned that these teeth felt 'slightly loose'.

The dentist noted the mobility and referred the patient to a specialist periodontist as he thought there may be a periodontal problem. Mr H demanded a referral to a specialist orthodontist to assess the situation. He expressed his concern about the outcome, his disappointment with the aesthetic result, and the discomfort he was now experiencing. He made it clear that he would seek legal advice should his concerns not be dealt with promptly.

The dentist contacted Dental Protection and requested our advice. Dental Protection reviewed all the treatment records and advised a way forward in order to resolve Mr H's concerns. Unfortunately, the treatment records suggested that the orthodontic assessment was inadequate and incomplete. The absence of a lateral cephalometric radiograph, lack of occlusal assessment, discussion of all relevant treatment options based on the orthodontic diagnosis, along with their advantages and disadvantages, not only compromised the care of the patient but also failed to demonstrate valid consent had been obtained.

The dentist's position was further weakened by the report from the periodontist who noted the poor position of the upper incisor roots, which had resulted in dehiscence and fenestration through the buccal cortical plate, which was likely to have occurred during the refinement phase.

Dental Protection informed the dentist of his vulnerabilities and requested a specialist orthodontic report, along with a remedial treatment plan. The dentist acknowledged he had not given sufficient attention to the orthodontic assessment. He also accepted his

role in causing the complications now evident as a result of agreeing to provide further treatment against his better judgement.

The dentist offered a refund of the failed orthodontic treatment and Dental Protection confirmed that the cost of the remedial orthodontic treatment phase would be paid on behalf of the member.

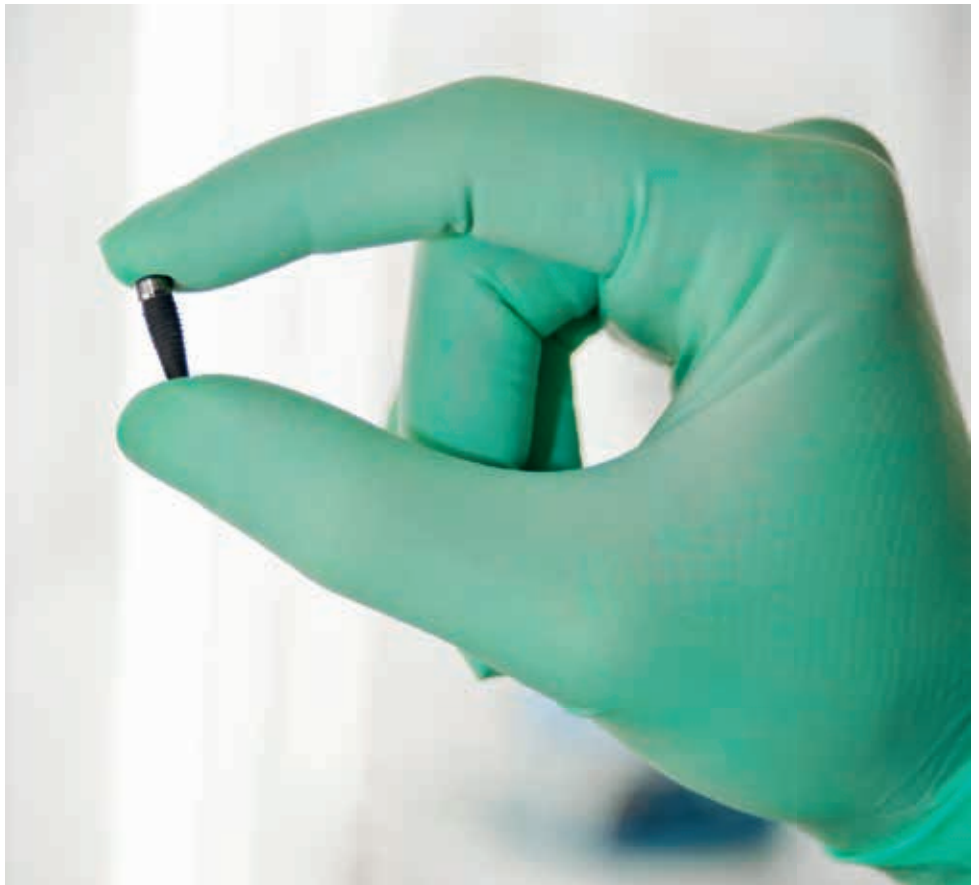Mr H continued treatment with the specialist orthodontist and was ultimately pleased with the final aesthetic result, which involved fixed upper braces and a further nine months of treatment. Mr H was therefore willing to accept the dentist's offer of a refund and reimbursement of remedial treatment costs, and the case was resolved.

LEARNING POINTS

- Ensure you provide a full orthodontic assessment, including exposure of appropriate radiographs and occlusal assessment, and offer appropriate treatment options, along with the risks and benefits of each.
- Ensure the patient is provided with adequate information and time to fully consider the treatment options – take the opportunity to rebook the patient when necessary.
- Beware of a demanding patient with high aesthetic needs – do not be pushed into providing treatment you do not feel is clinically appropriate or potentially damaging to the patient.
- Always provide an option of referral to a specialist colleague at the outset or in a timely manner, should the treatment not be progressing as you or the patient had intended or as expected.

Case study

Bridging the gap



danielzgombic/E+ via Getty Images

Mrs R attended Dr A's practice to discuss treatment options to restore her upper arch. She had lost a number of teeth in the buccal segments, as well as the 10, and the remaining anterior teeth were discoloured and heavily restored. The existing partial denture was worn and ill-fitting on account of recent tooth loss.

Options were discussed and a plan was agreed, including placing three upper implants and restoring the arch with a course of treatment involving crowns and bridgework. The patient was pleased with the prospect of being able to replace the partial denture with implant supported bridgework. The treatment was to include six crowns (6, 7, 8, 9, 11 and 14) as well as a further implant-supported crown to replace the 10, a cantilever implant-supported bridge at the 13 with a pontic at the 12, and a four-unit bridge supported by implants at the 2 and 5.

Dr A referred the patient to his colleague Dr B with a request to carry out the necessary assessment and to place implants at 2, 5, 10 and 13. In the meantime, the large restorations in the remaining teeth were investigated and replaced, as required by Dr A, to form a stable basis for the proposed crowns. A temporary denture was constructed, pending the completion of the definitive treatment.

On receiving the referral, Dr B duly saw and assessed the patient. The relevant investigations were carried out to ensure the feasibility of the implants requested and arrangements were made for the patient

to attend for treatment. The four implants were placed, under sedation, at the same appointment. The procedure was uneventful. Aside from some transient discomfort in the immediate postoperative period, the patient reported no major concerns or complications after the surgery.

The patient was discharged back to the care of Dr A to proceed with the restorative phase.

Once the healing was complete, Dr A commenced the crown and bridge treatment. During this, the patient reported problems "with the gum" around the temporary bridge and also occasional, poorly localised pain on the left side. There were plaque accumulations around the implant sites and temporary crowns so Dr A emphasised the need for meticulous oral hygiene. The final bridgework and crowns were eventually fitted by Dr A after some remakes and adjustments were carried out.

The patient experienced ongoing problems with the four-unit bridge and some months later sought a second opinion from Dr C, who advised the patient that the supporting implants were failing and recommended removal. The patient wrote to Dr A to demand a full refund for the treatment she had received from him and Dr B. Dr A then discussed this with Dr B before both dentists sought assistance from Dental Protection.

The patient's records were carefully reviewed to arrive at an accurate understanding of the situation. It was not immediately obvious that there had been any issue with the

original implant placement. The records of Dr A and Dr B were sparse in places. There was insufficient information to indicate that valid consent had been obtained, including the discussion of risks associated with the treatment. The findings of Dr C suggested that the occlusion and bridge design may have contributed to the failure.

The patient was clearly disappointed that the bridge had failed and was keen to have this replaced. After seeking advice, both Dr A and Dr B agreed to accommodate the patient's straightforward request for a refund of the cost of the failed implant-retained bridge, to prevent any further escalation.

LEARNING POINTS

- It is not always possible to establish the primary cause of implant failure, which can be multi-factorial. An implant may fail because of issues with the implant itself, the placement technique or factors connected to the restoration. The possible contributory causes need to be assessed before a decision can be made about how to manage the situation. Each case must be judged on its merits.

Case study

What's in a name



Dr W and her dental nurse Ms S were a formidable team. They had worked together for ten years in a reputable practice renowned for its patient-centric approach to care.

On one particularly busy day, Ms S seemed a little distant. Her lacklustre demeanour reflected her concern for a family member who had been taken ill the day before. By the time the fifth patient of the day was due they were running late and Ms S was setting up the surgery in preparation for the next patient who was attending for completion of endodontic treatment that had been started at a previous appointment.

Dr W reviewed her notes – written at the time of the first visit – and asked her nurse to call the patient, Mr F, from the waiting room.

When Mr F walked into the surgery, Dr W remarked that he was not wearing a suit and tie that day. She recalled that Mr F had been formally dressed on each of the previous visits, but today he was casually dressed. Dr W had noticed that Mr F appeared a little perplexed by her remarks but thought nothing of it.

Dr W advised Mr F that she hoped she would be able to complete his endodontic therapy and indicated that this would take approximately 45 minutes. Mr F was taken

aback by this and Dr W assumed that his reaction was probably related to her comment about the duration of the appointment.

Dr W applied some topical anaesthetic to the injection site with a cotton wool roll and it was only when she examined the tooth, she noticed it was unrestored. This set alarm bells ringing and she realised that the wrong patient was sitting in the chair.

Dr W apologised to Mr F and explained that another patient with the same name had recently undergone the first part of root canal therapy and this had caused the confusion. Mr F was not prepared to accept the apology and said he wished to make a formal complaint.

Dr W contacted one of the dentolegal consultants at Dental Protection who assisted her with a written response. It was explained to Mr F that it was a coincidence that both Mr Fs had been booked in on the same day at similar times and were due to see different dentists. When the nurse had called for Mr F in the waiting room, the 'wrong' Mr F had stood up and the nurse, normally quite vigilant, had not noticed given her preoccupation with a family member's illness.

The written response was accepted as a reasonable explanation and he was content

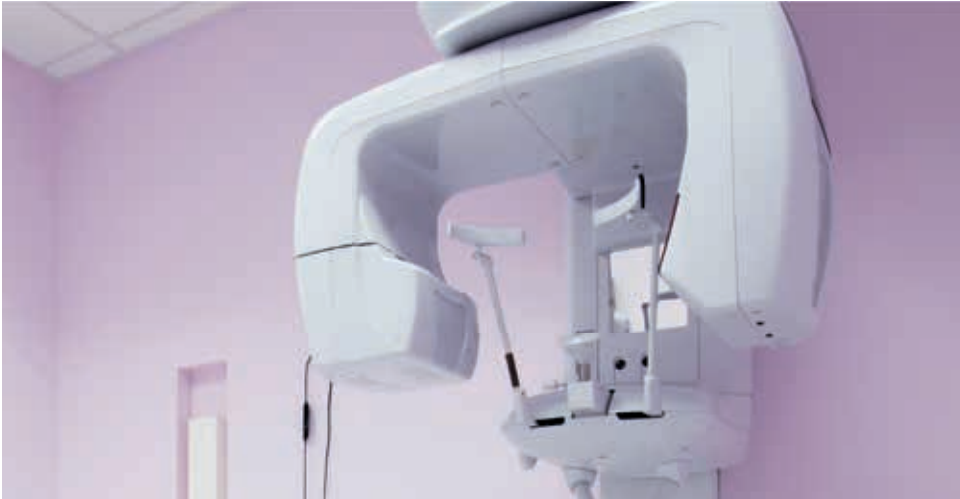to let the matter drop. He indicated that he had lingering concerns about what had happened and had interpreted the event as a risk that he might have received someone else's treatment and on this basis said that he would not be returning to the practice.

LEARNING POINTS

- When patients are known to the dentist, this type of error is unlikely to arise. It is more likely when the patient is new or has only seen the dentist a few times and the visual image of the patient has not yet been committed to memory.
- There should be other means of confirming identities in situations where the patient is not known to the dentist.
- Patients in the waiting room may be hard of hearing and may mishear the name that is called.
- Checking and confirming the identity at the outset can save embarrassment later.

Considering CBCT

One of the most spectacular examples of new technology in modern dentistry is the increasing use of cone beam computed tomography (CBCT). Dentolegal consultant Jim Lafferty looks at important aspects of the technique.



The improvements in assessment, diagnosis and treatment planning from the use of CBCT are well known. In the fields of implant placement and third molar surgery we have seen significant uptake, and our endodontic specialist colleagues are now also seeing the benefits and how it can improve results for patients.

The use of such technology to improve patient care and reduce risk will be an attractive proposition to all involved, but there are potential pitfalls. Awareness of these is vital, particularly given the high costs associated with purchases of this type.

There is a considerably higher exposure to ionising radiation that increases the risk of developing a malignancy, so we should all be able to justify why any CBCT is being used, even if you are prescribing the imaging to be taken elsewhere. In some jurisdictions there is now a legal requirement to record this justification in writing. Members in those (countries/markets) report that this means they are more careful to consider both the benefits and the risks associated with CBCT. As a result, they have reduced the numbers of CBCT images they take, reducing the amount of exposure to ionising radiation.

If you are responsible for assessing the resulting image, you should ensure that you can demonstrate that you have suitable training for this and make a written record of the assessment. There are enormous

amounts of information to be gleaned from these images and the person reviewing the slices has the responsibility to check for pathology in all those slices – even at sites distant to the area of interest.

In the accompanying case report, you will see that it is very important to establish who will be reporting on the image.

The key points dentists should consider in the area of CBCT are:

- **Arrangements** – who will be responsible for reporting?
- **Assess** – a CBCT without clinical examination is very difficult to defend.
- **Balance** – the risks of ionising radiation against the clinical information gained.
- **Minimise** – can the same information be obtained with a lower dose x-ray?
- **Justification** – record in writing the reason for taking the x-ray.
- **Report** – there should be a written report, leading to the normal recording of diagnosis, treatment options discussion, risk discussion, treatment planning and consent.

Case study

Mr D was referred to an oral surgeon for pain related to his temporomandibular joint issues. During the early assessments a CBCT was prescribed, carried out in a remote CBCT and imaging centre and a specialist radiologist report ordered. Over a year later, a further CBCT was ordered from the same centre when symptoms had spread.

The patient went on to develop a cancerous neuroma in his tongue, which by now had spread into the lymph nodes, and was considered inoperable.

The family complained to the regulator, and the oral surgeon contacted Dental Protection. He was particularly concerned as his records of the patient's treatment were somewhat brief and generally of a low standard. However, with assistance from Dental Protection, the member was able to show that he had ordered specialist reports and that the developing neuroma had been missed in the original scan. It was put forward that the responsibility for failing to diagnose the tumour was not the oral surgeon's. We then worked closely with the member on developing a CPD programme around record keeping so that, by the time of the hearing, he was able to demonstrate that he had shown insight and taken steps to remediate.

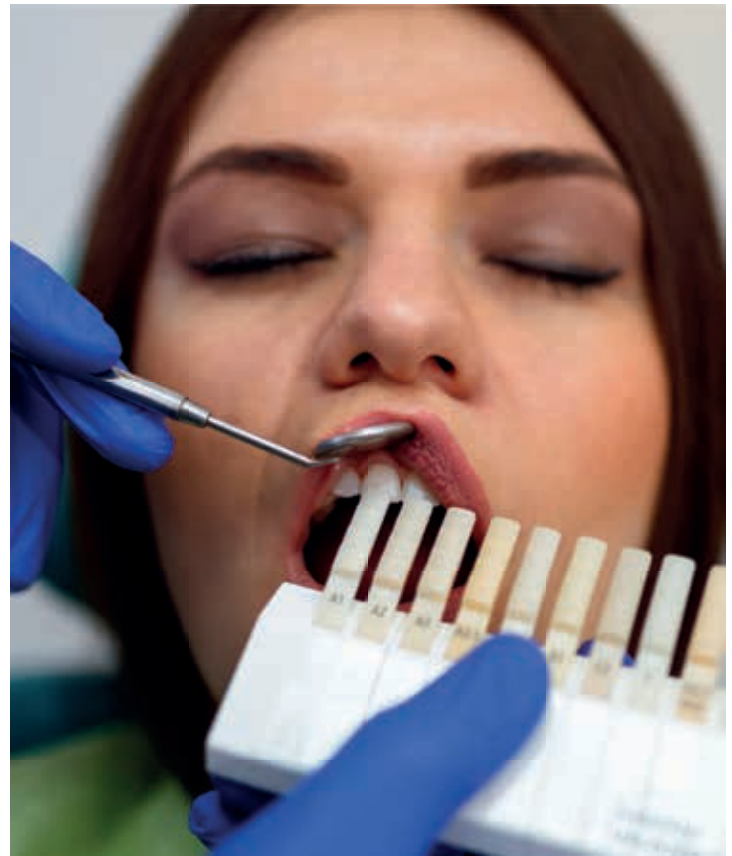
Naturally the member was keen to emphasise in his response to the Dental Council how distraught he was at hearing the news, but he did not consider the complaint showed any wrongdoing on his part. This was recognised by the Dental Council and the case was dismissed.

LEARNING POINTS

- All radiographs should have a written report.
- By having the image reported on by an appropriate specialist, the responsibility for spotting pathology outside the area of interest is not the dentist's.

Case study

An unexpected surprise



MilanXPO/E+ via Getty Images

Ms C visited her dentist, requesting an improvement on her overall smile and the specific appearance of the upper lateral incisors, which had been restored with porcelain veneers some years previously and the colour match with the natural adjacent teeth was now unsatisfactory.

Ms C, an aspiring actress, who now lived overseas, had been regularly attending this particular dentist since childhood. The dentist had placed the existing veneers more than 12 years earlier to improve the appearance of the peg-shaped lateral incisors. At a previous visit Ms C had obtained some home tooth whitening gel to lighten her teeth which exaggerated the colour mismatch against the veneers.

She told the dentist she wanted all of her teeth to be a uniform and much lighter colour. When the dentist removed the existing veneers he noted the underlying vital tooth structure was particularly dark. He had recently treated a patient with a similar problem, and so was acutely aware of how challenging it was to replace veneers and achieve the desired result to the satisfaction of the patient.

He made a decision to provide a full coverage zirconium crown on each lateral incisor. At the fit appointment, he failed to check the contact point distally at 22 and failed to notice that this crown was not seated correctly. Ms C returned a few days later complaining of sensitivity and was aware of a deficient margin palatally which she could feel with her fingernail. It was agreed that this crown would be replaced, but it

proved difficult to arrange an appointment to undertake this treatment given the patient's overseas commitments.

The sensitivity continued, so Ms C obtained a second opinion and was advised that both crowns had not been fitted correctly. The report from the new dentist was supported by radiographic evidence confirming a substandard marginal fit – which explained the sensitivity reported. The crowns were replaced by the new dentist and a letter of complaint was sent to the original dentist from the patient. She clearly felt that she had been more involved in the latest treatment decision than she had been when the zirconium crowns had been discussed, stating that she had not been fully informed about how much of the additional tooth would be sacrificed in order to accommodate the crowns, and what impact this might have long-term. She failed to mention that the dentist had been willing to rectify the situation, and that it had been her own diary commitments that had delayed the provision of remedial treatment.

The dentist contacted Dental Protection for advice and assistance on how to manage the complaint. He explained that Ms C was now seeking a refund of fees and a further payment to cover the cost of her remedial treatment. Notwithstanding his offer to replace his faulty work, he felt it was unfair that he should be expected to pay for the remedial treatment as well. Having lost the trust of the patient, the dentist lost the chance to recover the situation, particularly where there was factual evidence of a poor fit. He also accepted that the consent

process had been undermined by his failure to identify how much information the patient needed, specifically around the long-term risks attached to a more aggressive tooth preparation compared with a like-for-like replacement of two veneers.

In her complaint, the patient stated that had she been given the correct information, she would have made a different decision. Our assessment of this particular case was that it was unlikely the patient would settle for a refund of fees and with this in mind Dental Protection made a significant contribution towards the remedial treatment costs.

LEARNING POINTS

- The law on consent provides a framework that protects patients' rights to make an informed decision about all aspects of their treatment. In this case, the choice of zirconium crowns instead of veneers was not adequately discussed, nor was there anything in the records to defend the dentist's position. Had the patient obtained legal advice, she would have been told of her right to compensation and it made no sense to allow this situation to escalate, where legal fees would dwarf the cost of paying for the remedial treatment.

Dental
Protection



HERE TO PROTECT YOU AND YOUR PROFESSIONAL REPUTATION

Learn how to manage your risk
and improve patient safety

Our **FREE** risk prevention tools and
techniques include:

- Online learning
- Lectures and seminars
- Workshops

REGISTER TODAY AT
DENTALPROTECTION.ORG/PRISM

Find us on   @MPS_Dental

CONTACTS

You can contact Dental Protection
for assistance **dentalprotection.org**

Membership services

Telephone +44 113 241 0727

caribbeanandbermuda@medicalprotection.org

Dentolegal advice

Telephone +44 207 399 1400

enquiries@dentalprotection.org

Dental Protection Limited is registered in England (No. 2374160) and is a wholly owned subsidiary of The Medical Protection Society Limited (MPS) which is registered in England (No. 36142). Both companies use 'Dental Protection' as a trading name and have their registered office at Level 19, The Shard, 32 London Bridge Street, London, SE1 9SG.

Dental Protection Limited serves and supports the dental members of MPS with access to the full range of benefits of membership, which are all discretionary, and set out in MPS's Memorandum and Articles of Association. MPS is not an insurance company. Dental Protection® is a registered trademark of MPS.